


<h1>Female Test Results</h1>		Not-for-Profit BSI International Clinics  Integrative Natural Health	
<h2>Live Blood Microscope</h2>			
Patient Name:		Age:	
Doctor:		Specimen Date:	04 June 2026

Live Blood Microscopic Observations

I	N	I = At Issue N = Not at issue	
	✓	Vital Force	Speed of movement Moderate
	✓	Serum	Concentration Moderate
Red Cells			
	✓	Red Cell Stress	Cell Shape Round Cell Stress Average 4-5
	✓	Red Cells Clotting	Clotting Normal
	✓	Red Cells Rings	Rack Focus: No. Of Rings Counted 6-7 Size of cells Normal
	✓	Rouleux	Straight Low Erratic Level 2-3
	✓	Acanthocyte D-H	Amount Observed Low Consider liver diseases or congestion
	✓	Agglutination D-H	Amount Observed None Consider acute infection, virus elimination, cancers
	✓	Basophilic Stippling D-H	Amount Observed None Consider poisoning, and low red cell production from bone marrow, thalassemia, cancers
	✓	Boat-shaped cell	Amount Observed None Only if static in sample. Consider Sickle cell diseases
	✓	Cabot's Ring	Amount Observed None Consider B-12 anemia and related diseases, megaloblastic anemia, myelodysplastic syndrome, and lead poisoning.
	✓	Crystal Formation in Red Cells	Amount Observed None Consider intoxications in red cells from environmental contaminations and or diet.
	✓	Dacryocyte / Poikilocyte / Teardrop	Amount Observed None Only if static in sample. Consider Particular dyserythropoietic disease states, megaloblastic anemia and myelodysplasia
	✓	Elliptocyte D-H	Amount Observed None Consider iron deficiency or chronic disease.
✓		Echinocyte / Burr Cells D-H	Amount Observed Low Consider CV-19 inoculations, some street drugs, renal failure
	✓	Hypochromia	Amount Observed None Consider iron deficiency, heavy metal poisoning
	✓	Howell-Jolly Body D-H	Amount Observed None Consider normal neonates, celiac disease, bone marrow transplant or abnormalities, Pregnancy
	✓	Irregularly Contracted Cell D-H	Amount Observed None Consider Thalassemias, infiltrated bone marrow: (look also for white cell precursor cells), leukemia, myelofibrosis, or infiltrating solid tumor.
	✓	Keratocyte	Amount Observed None Consider disseminated intravascular coagulation (DIC), thrombotic thrombocytopenic purpura (TTP), renal disease particularly vasculitis, disseminated malignancy
	✓	Macrocytes	Amount Observed None Consider Vitamin B12 deficiency (most commonly due to impaired absorption) 2. Folic acid deficiency

	✓	Ovalocyte	Amount Observed None	Consider Myelodysplasia, iron deficiency, etc. May indicate previous malarial parasites.		
	✓	Pappenheimer Bodies	Amount Observed None	Consider, only when in large numbers, excess iron, Hemoglobinopathies (thalassemia), sideroblastic anaemia, vitamin B12 deficiency, vitamin B6 deficiency, alcohol excess, anti-pyridoxine therapy, chloramphenicol, mitochondrial disorders		
	✓	S-C Poikilocyte	Amount Observed None	Consider heterozygote disorder (HbSC disease), lesser anemias, sickle cell diseases		
	✓	Schistocyte (Fragment)	Amount Observed None	Consider microangiopathic hemolysis, thrombotic thrombocytopenic purpura, hemolytic uraemic syndrome, pregnancy associated - HELLP syndrome (hemolysis, elevated liver enzymes and low platelet count), or pre-eclampsia. Disseminated intravascular coagulation, myelofibrosis, turbulent blood flow, valvular heart disease, hemangiosarcoma, fragile erythrocytes, congenital dyserythropoiesis, myelodysplasia, severe hematinic deficiency, severe membrane disorder		
	✓	Sickle cell	Amount Observed None	Consider hypoxia, sickle cell disease		
	✓	Somatocyte	Amount Observed None	Consider South East Asian Ovalocytosis. Excess alcohol intake, advanced liver disease, potassium loss		
	✓	Spherocyte	Amount Observed None	Consider all hemolytic anemias, severe burns		
	✓	Micro-spherocyte	Amount Observed None	Consider toxin induced membrane damage: particularly Clostridium perfringens, and megaloblastic states		
	✓	Target Cell	Amount Observed None	Consider macrocytosis that may imply liver disease; or if MCV is normal or low consider a hemoglobinopathy (HbC, D or E). Lipid disturbance related to liver disease, hepatic cirrhosis, alcohol		
White Cells / Biologicals / Artifacts						
	✓	Neutrophils	Amount Observed Moderate	Cell Contents or Activity Semi-Active		
	✓	Lymphocytes	Amount Observed Moderate	Cell Contents or Activity Semi-Active		
	✓	Monocytes	Amount Observed Moderate	Cell Contents or Activity Demi-Active		
	✓	Stem Cells	Amount observed Average			
✓		Bacteria	Differentiated Vol None	Non-Diff d Vol Low	Beneficial Bacteria None	Fermentation Volume Observed
	✓	Fungus D-H	Light Volume None	Fungus + Bacteria None	Candida Albicans None	
✓		Parasites D-H	Ameba 4-5	Paramecium 0	Spirochetes 0	Rare Round Parasites 0
	✓	Fibrins D-H	Volume None			
✓		Graphene Derivatives D-H	Observed	Type Graphene Hydroxide		
	✓	Crystals (outside of red cells)	Concentration Low	Toxicity Level 2	Color / Type Black	
	✓	Basic Cancer Indicators, as viewed in blood under microscope. D-H	Concentration None	Descriptions and Relevance		
	✓	Artifacts D-H	Volume None	Toxicity Level	Color / Type	

Echinocyte / Burr Cells: Always remember that echinocytes may be an artefact of blood storage or of cells on the edge of a live mount slide (artefactual echinocytosis), so look at the condition of other cells on the film and determine whether the echinocytosis is patchy in distribution. Where genuine there will usually be a significant systemic disease present. This most frequently will be renal failure.

<https://haematologyetc.co.uk/index.php?title=Echinocytes>

Artefact

Prolonged storage of sample before spreading
Glass/Ph effect
Slow drying

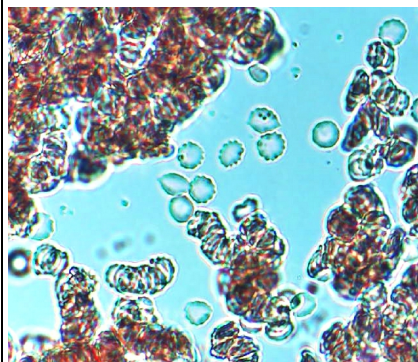
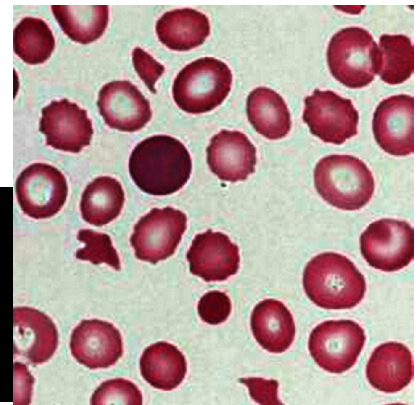

Energy depletion

Pyruvate kinase deficiency (note that the cells also resemble acanthocytes – the abnormal forms being prominent only after splenectomy). See Clinical Image.

Altered hydration

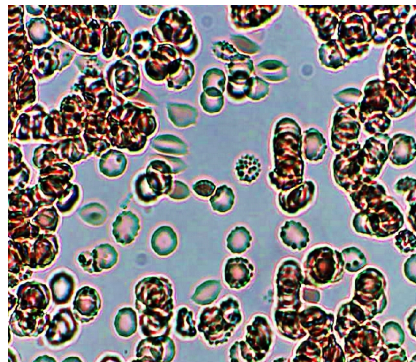
Renal failure
Electrolyte imbalance
Diuretic treatment
Altered membrane composition
Drugs (doxorubicin)

EXAMPLE



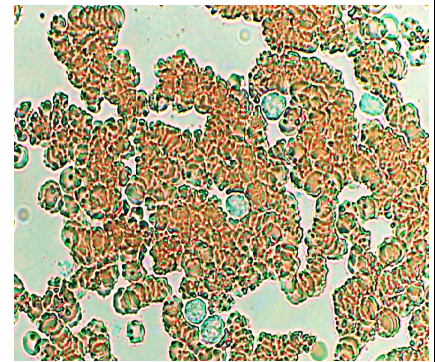
Un-stained stem cells with burr cells with highly clotted red cells. Indicative of an acidic condition.

Only consider this condition if the cells appear far within the sample. If these cells appear near the very edge of the live sample slide, then burr cells should be ignored, as exposure to oxygen and dehydration can also cause this condition.



Burr cells with boat-shaped cells.

Together this condition would indicate a possible serious blood disorder and exposure to heavy toxins, such as street or prescription drugs, etc.

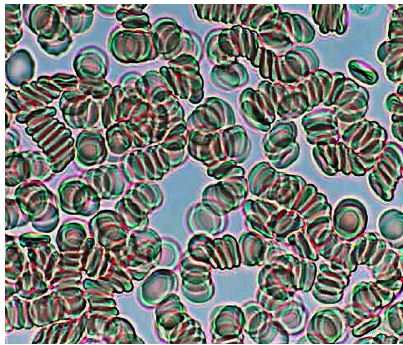


Unhealthy blood. Many Burr cells in non-differentiated Rouleux. Note also the internally-broken, or burst neutrophil cells.

This would occur in heavy radiation, both ionizing and non-ionizing. Also heavy chemical contamination.

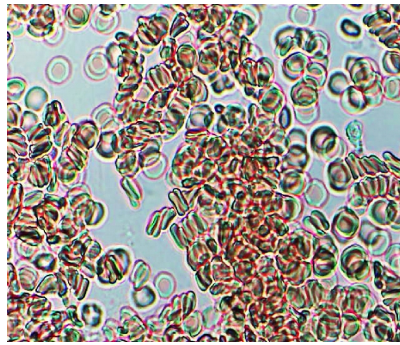
Rouleux Red Cell Formations, Indicating Hibernation of Red Cells

EXAMPLE



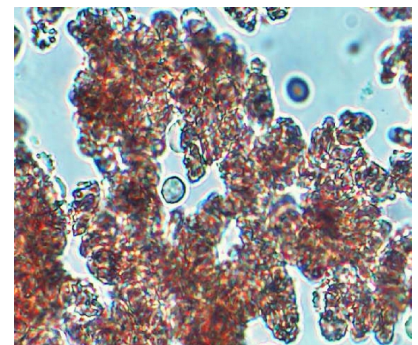
Healthy, recoverable, Rouleux red cell formations. Cells are hibernating.

Always locate and photograph the best quality sample for this analysis.



Combination of un-recoverable Rouleux with a few recoverable cells. Notice the stem cells, that of course do not clot.

Can you spot the ameba?



Erratic non-recoverable Rouleux red cell formations. Also indicates heavy clotting

Vital Force / Prana / Qi

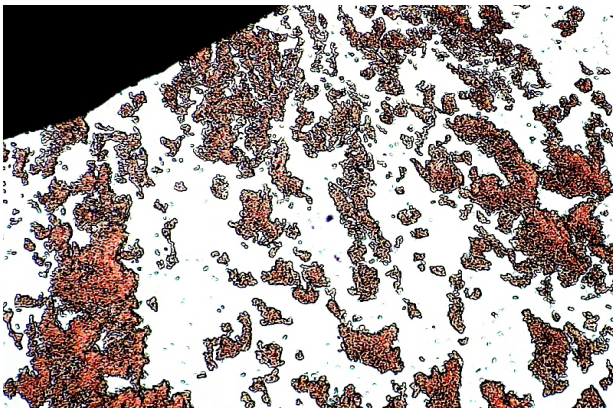
This is more an indication of serum versus blood cells balance. However a healthy and vibrant person will produce stronger and sustained blood movement than will a person who is dehydrated, under-nourished, does not exercise, suffers from stress issues of all types.

Vital Force is universal life-giving energy, the underlying force behind our physical, mental, and spiritual well-being. Vital Force is a subtle, pervasive energy that powers various aspects of our being. Much like a discharged battery, insufficient life-force energy flowing through the body can create disharmony on physical, emotional, and spiritual levels.

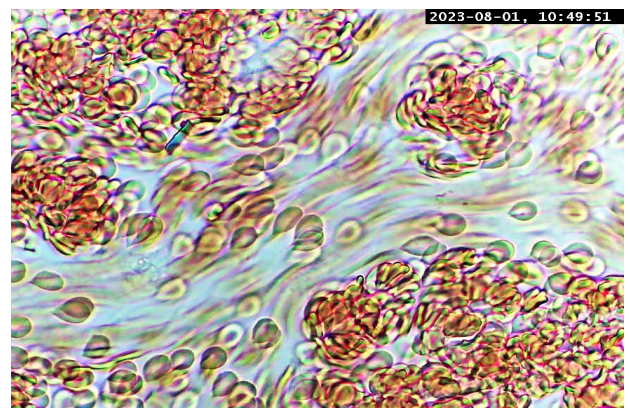
It is present in the oxygen we breathe, in food, water, and the sun's energy that nourish all living beings. We can increase and balance life-force energy through deep breathing exercises, meditation, and connecting with nature.

Low Vital Force. Often related to and indicative of fatigue and weakness, poor concentration and memory, dizziness and vertigo, emotional imbalances, digestive issues, accelerated aging.

To Increase Vital Force. Effective impact exercise, adaptogen medicines, healthy eating, stress management. **EXAMPLE**



Very low Vital Force. No movement to the sump (black) area of the slide. Also indicates low serum / dehydration. Heavy clumping with resultant low oxygen saturation for the blood and the tissues it nourishes.



Excellent Vital Force. Notice the non-differentiated Rouleaux, generally not seen where there is high vital force movement. Ignore teardrop-shaped cells when blood is moving fast.

Stem / Stab / Band Blood Cells

<https://www.ncbi.nlm.nih.gov/pmc/articles/PMC6119634/>

Stem cells will appear like red cells, but do not clot and display a large white center.

Hematopoietic stem cells (HSC) emanate from bone marrow and can produce all the cells that function in the blood. Stem cells also can become brain cells, heart muscle cells, bone cells or other cell types. They circulate under steady state conditions in peripheral blood to...

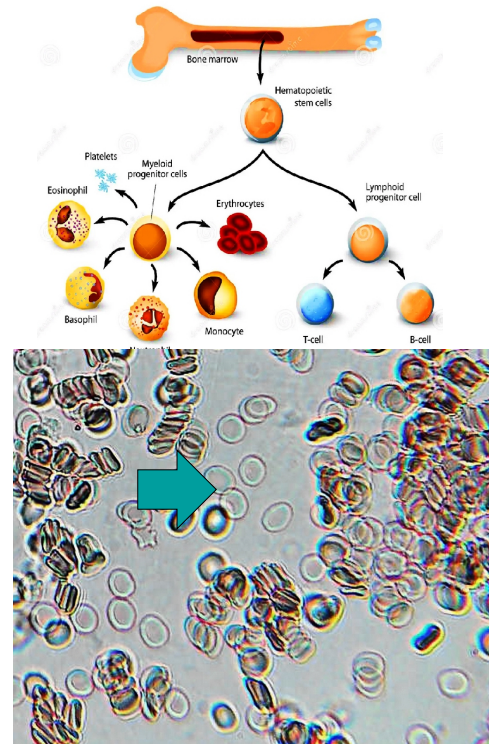
- 1) To maintain a stem cell pool in remote bone marrow locations in the body and
- 2) To "patrol" peripheral tissues and organs and, when needed, to respond to organ injuries and pathogens. The number of these cells increases in stress situations related to pathogenesis, inflammation, organ injury as well as after strenuous exercise.

Myeloid and Lymphoid Progenitor Stab or Band Cells, as observed in blood under microscope at BSI, serve as an analogue observation of HSC cells. Large or small quantities will also loosely indicate the quality and quantity bone marrow production of HSC.

Bandocytosis (Low count): Possible neutropenia due to inadequate maturation of stem cells, most likely indicates some type of viral elimination. Stab cells, more formally called "band cells," are blood cells which are in the formation stage. These types of white blood cells are quite young and have only recently been produced and released into the bloodstream by the bone marrow. Can also indicate sluggish or compromised immunities.

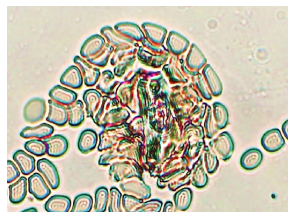Bandemia (High count): Immune system and bone marrow are working hard to produce stem cells, strengthening the immune system due to long term virus. If other types of white blood cells are outside of scale this is can also be an indication the body is now overcoming continuous viral elimination. Can also indicate the Immune system is strong. If solely high too many white blood cells are maturing, or can be due to an uncontrolled overgrowth of pathogens. Look for blood diseases if solely high.

EXAMPLE



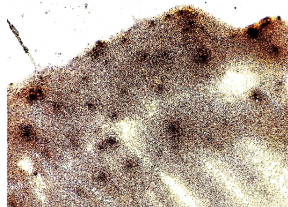
Crystal Structures in Blood

EXAMPLE

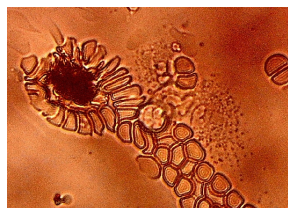

A softer, not yet fully defined crystalline structure. Moderately toxic, affecting at least two layers of surrounding cells.

The green color may indicate copper or other another mineral that would appear green when oxidizing.



A heavy contamination along the edge of a blood smear. Usually carbon, related to smoking or street exhaust exposure.



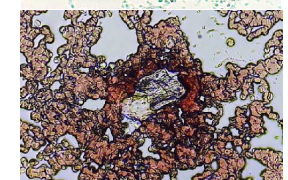
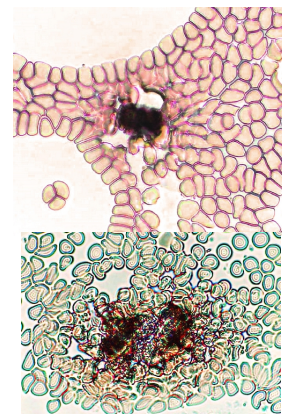
A magnetic crystal, most likely iron or graphene, which has magnetized surrounding ferritin-containing cells.

Also an intact neutrophil cell, surrounded by other neutrophil cells what are overwhelmed and consumed by errant bacteria.

Low to moderate toxicity crystal, probably carbon - the most common of blood solids contaminants. Notice that it is affected surrounding red cells, there appears to be an exchange of elements between them. This was probably inhaled by the patient, which is of course immediately transferred to blood from the lungs.

Moderate to high toxicity crystal formation. Consuming red cells, and acidic due to the mottling it is causing on surrounding cells.

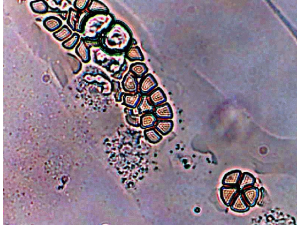
High toxicity crystalline structure, affecting multiple layers of red cells. It appears to be repelling iron or hemoglobin. It may also be absorbing serum or water, in dehydration of surrounding cells. Due to the lighter color of the structure, the structure may be of one of the lighter elements.



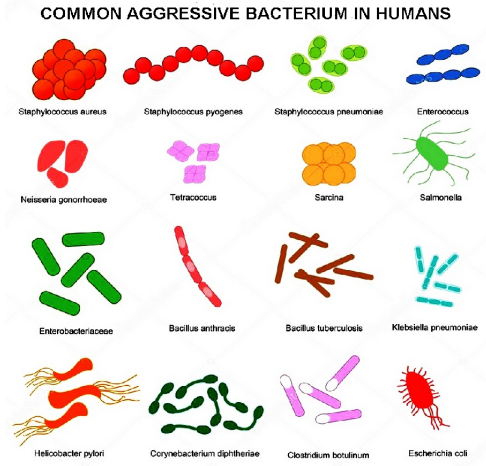
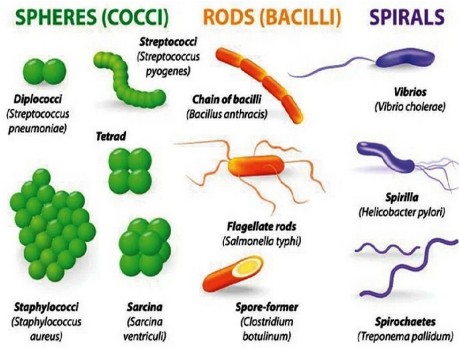
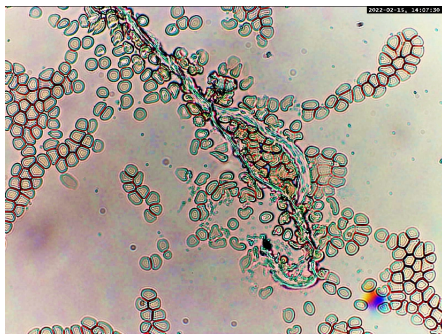
Bacterium in Blood - The First Level of Immune Defense

It's important to remember that bacteria are always present in all areas of the body, and vital to proper function. Bacteria will mutate from so-called good concentrations or balance, to more aggressive concentrations when the body needs to fight off pathogens. Good bacteria can go on the offensive but not actually bad, unless out of control due to continued consumption of its causes. Bad or offensive bacteria can again become benevolent, as the body creates the right balance to custom heal a particular pathogen imbalance.

Bacteria surround and consume pathogens. Along with fever, they can bake-out invading disease.



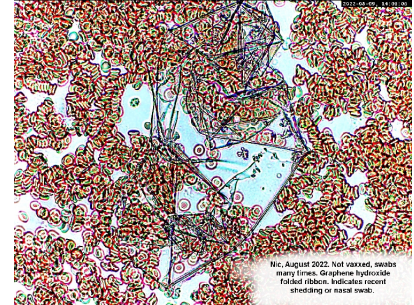
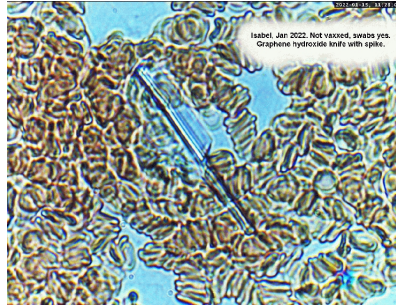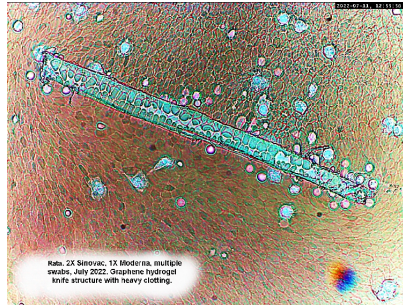
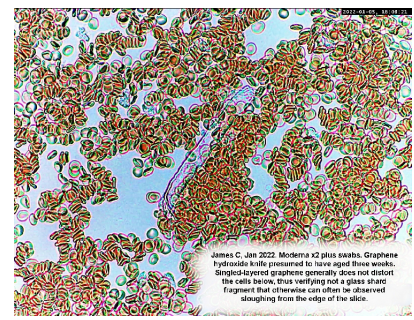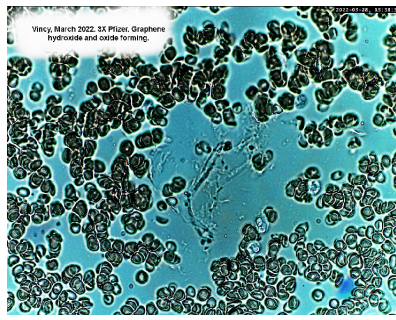
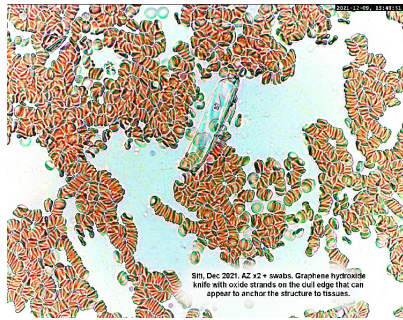
EXAMPLE



Covid Inoculations Artifacts

Graphene Hydroxide

EXAMPLE



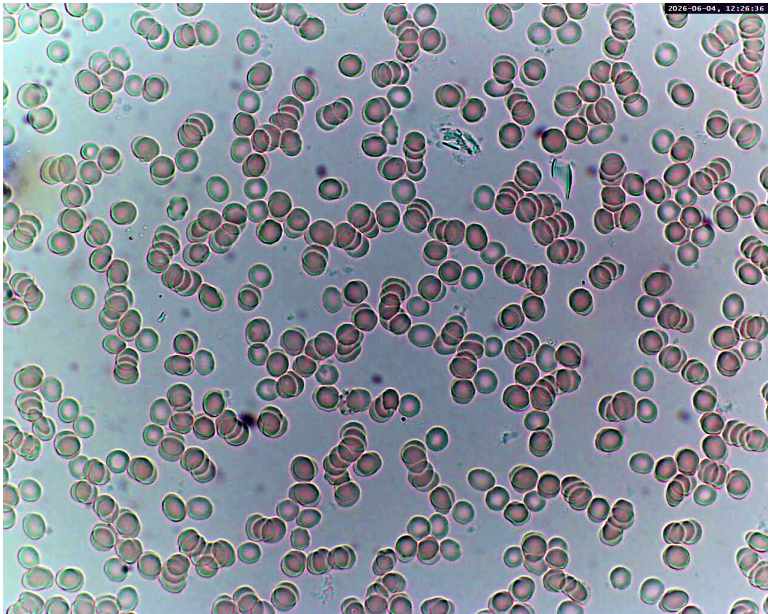
Dr. Andreas Noack is a German expert in graphene nano structures. He describes these nanoscale structures as “tiny razor blades”. Only one atom layer thick, they are relatively wide and long. Fortunately we have observed their consumption by white blood cells, known as lymphocytes, in people with intact immune systems, these structure do deteriorate over time in a healthy, immunities-intact body.

Noack goes on to say, “So these razor blades spread homogeneously in (blood serum). This is basically Russian roulette. It cuts the blood vessels. The blood vessels have epithelial (inner skin) cells as their inner lining. The epithel is extremely smooth (and very thin), like a mirror - and it is (easily) cut up by these razor blades. That is what’s so dangerous. These are the sharpest imaginable structures because they are only one atom layer thick.”

“(We have seen) pictures of coagulated blood coming out of the nose. People bleed to death on the inside. Especially the top athletes who are dropping dead have fast flowing blood. The faster the blood flows, the more damage the razors will do.”

The photos below are for reference only, and in support of test results produced by the BSI Laboratory.

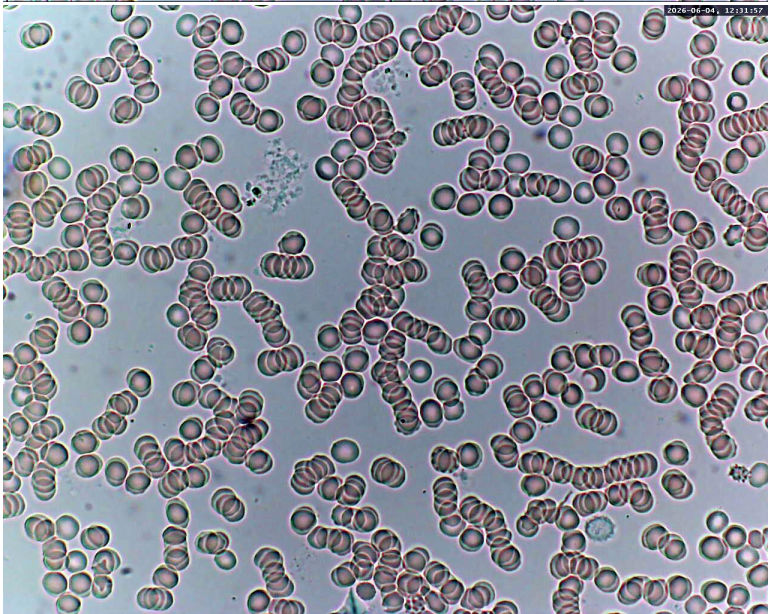
PATIENT MICROSCOPE LIVE BLOOD OBSERVATIONS



Graphene hydroxide observed

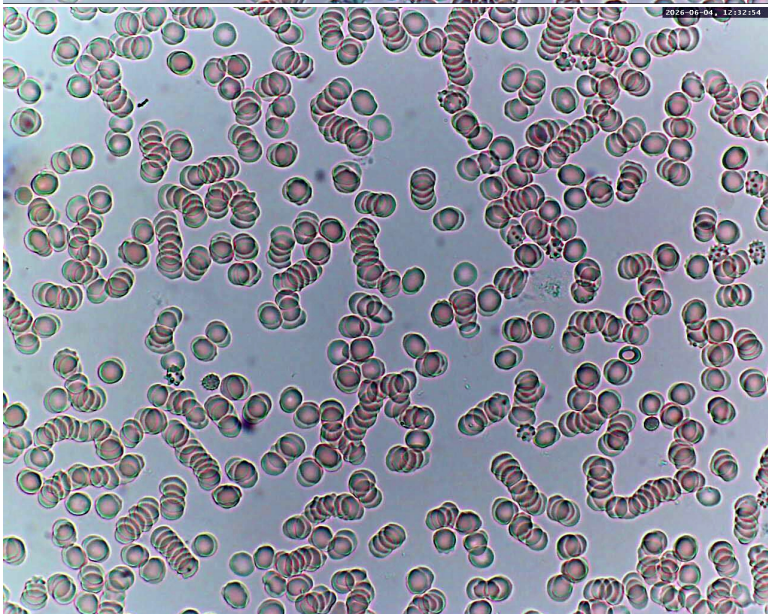
Many stem cells observed

Vital force good



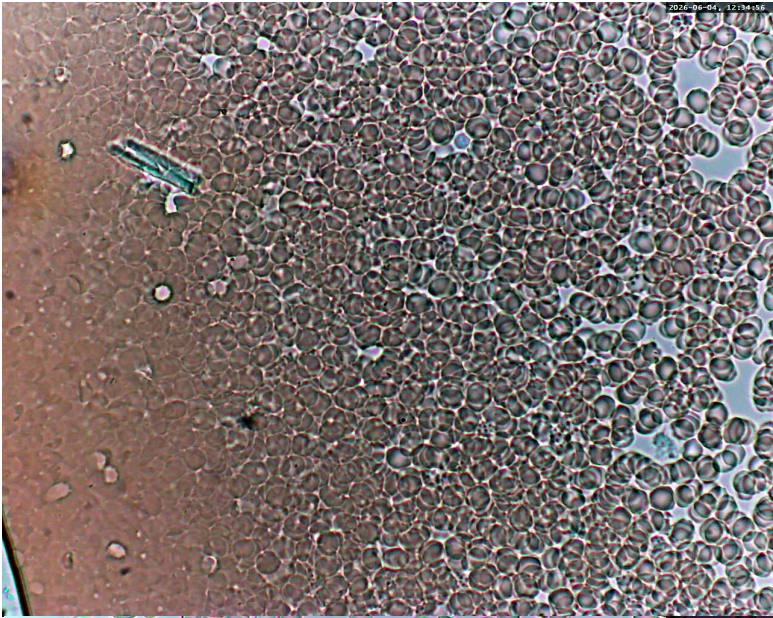
Macrophage cells

Rouleux red cell formations



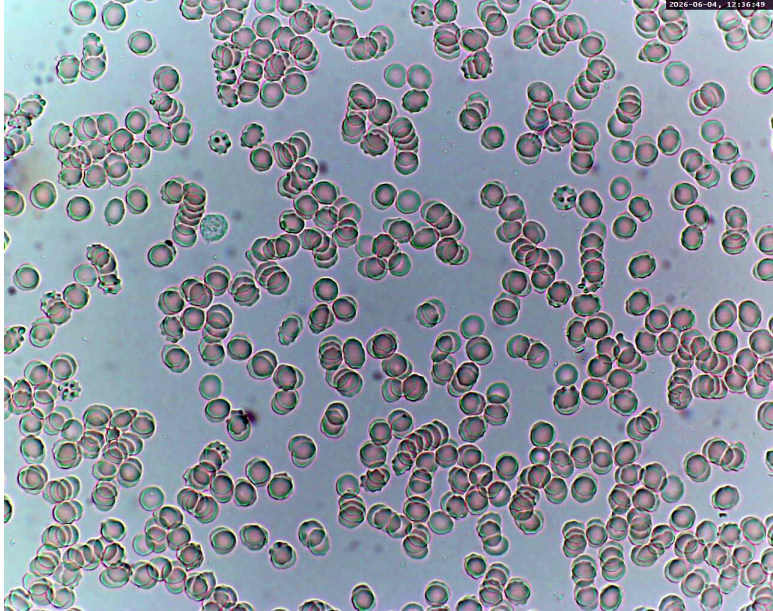
Burr cells observed

Rouleux red cell formations



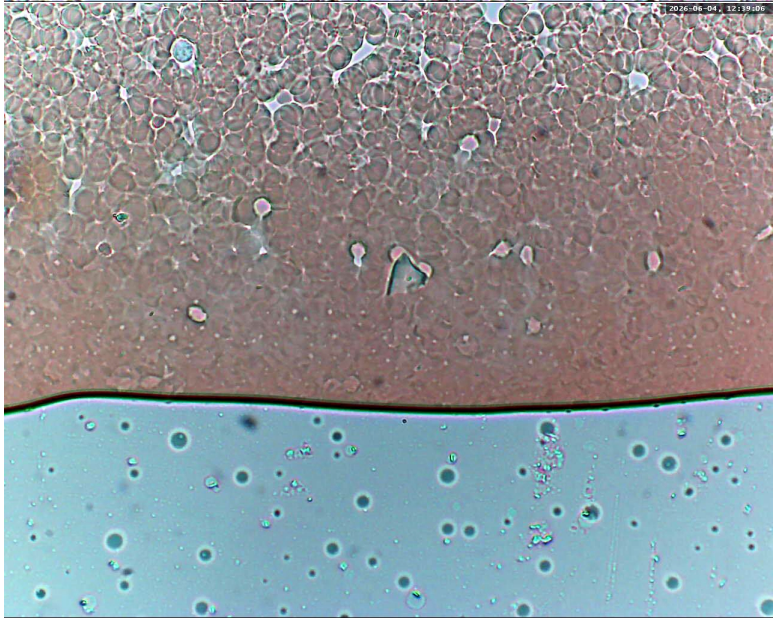
Graphene hydroxide

Lymphocyte cells



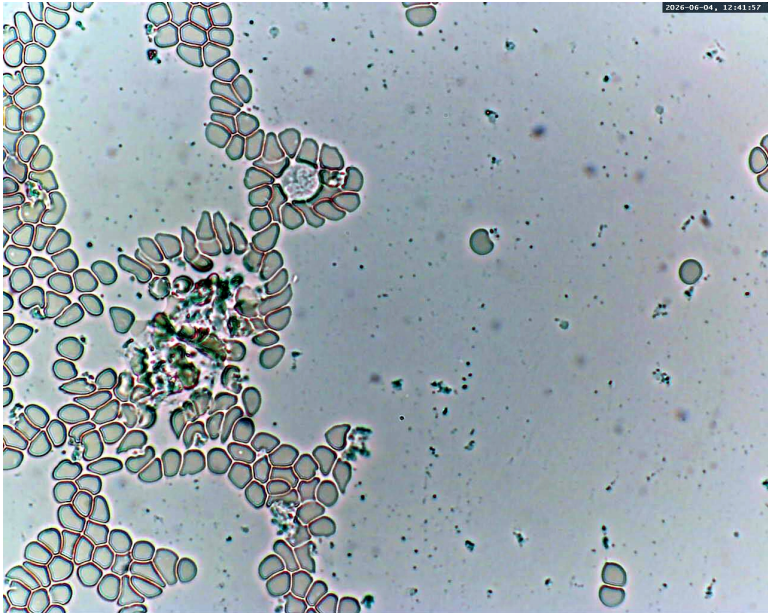
Burr cells observed

Macrophage cell observed



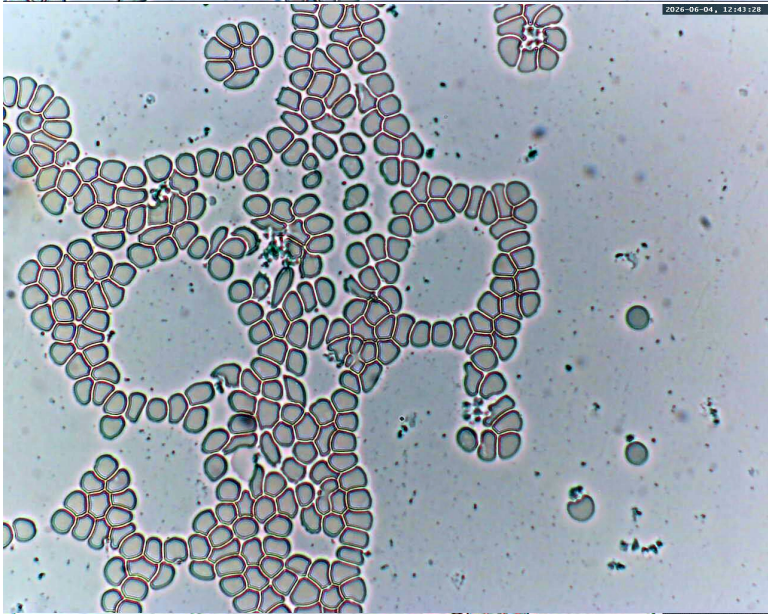
Lymphocyte cells

Graphene hydroxide

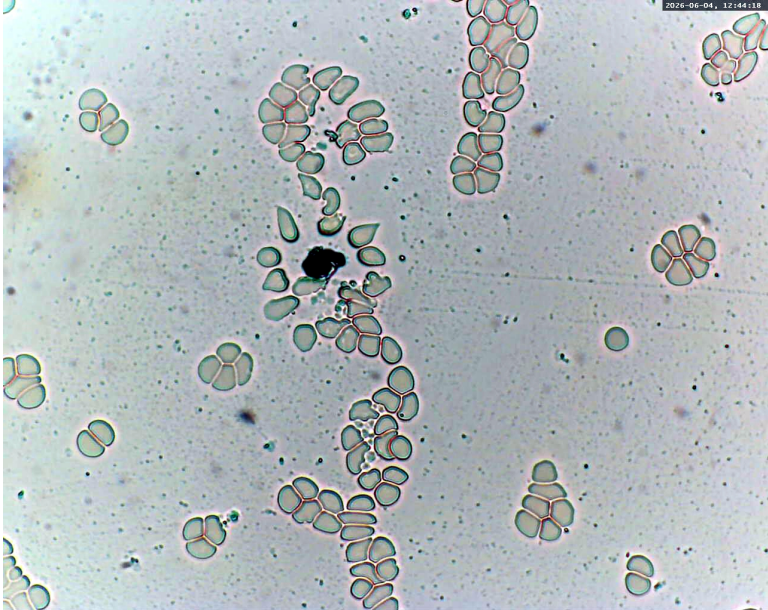


Semi active immune cell

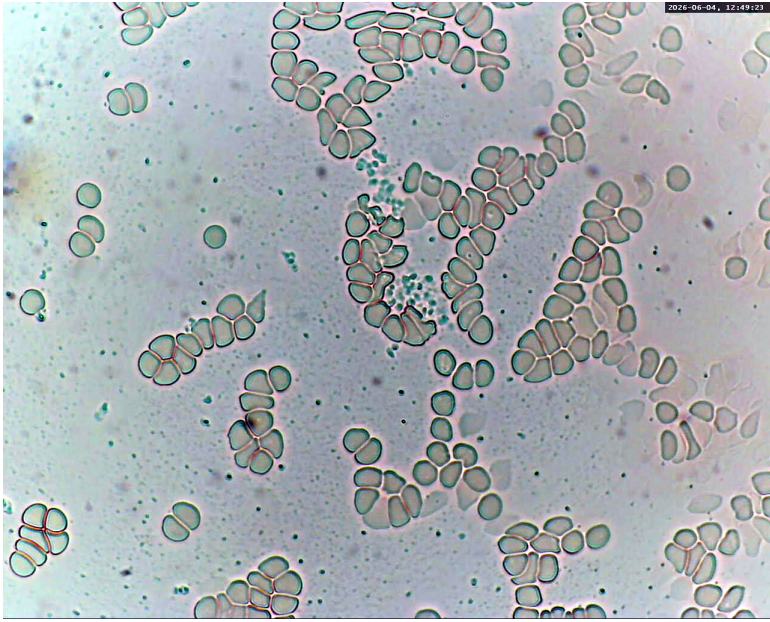
Remnant of black carbon crystal
Non-differentiated, non-beneficial
bacterium toxicity



Non-differentiated, non-beneficial
bacterium toxicity



Carbon crystal low toxicity, possibly from
exhaust or air pollution



Non-differentiated, non-beneficial
bacterium toxicity